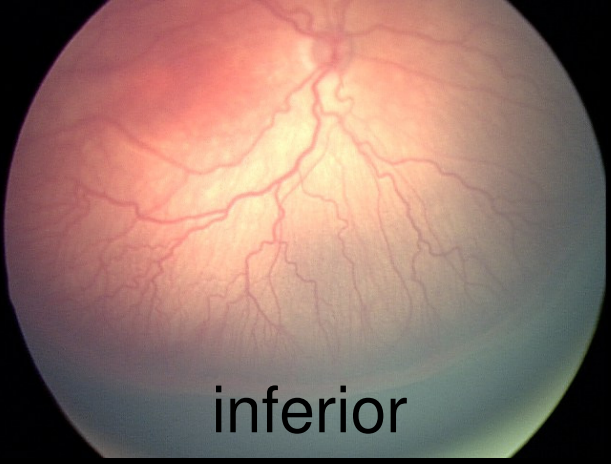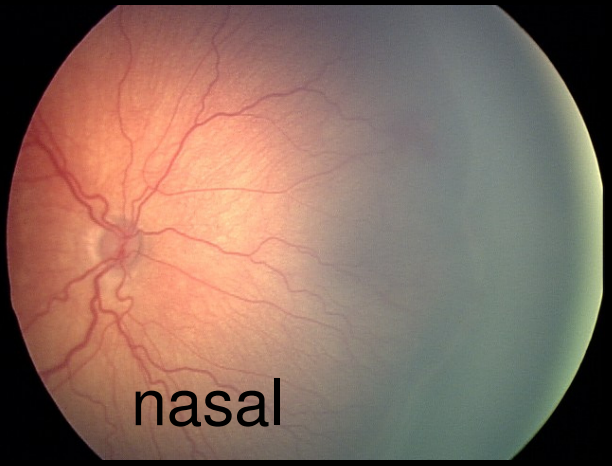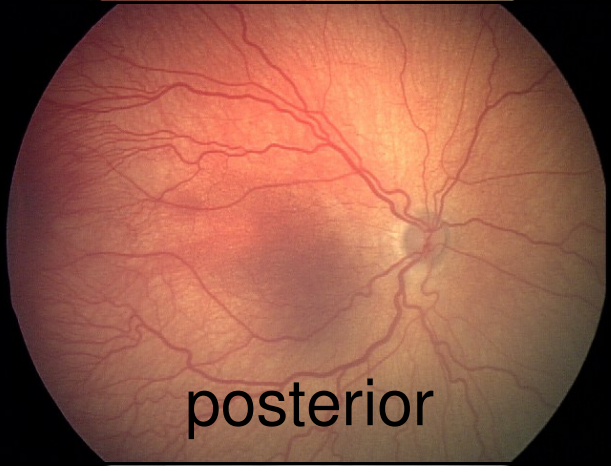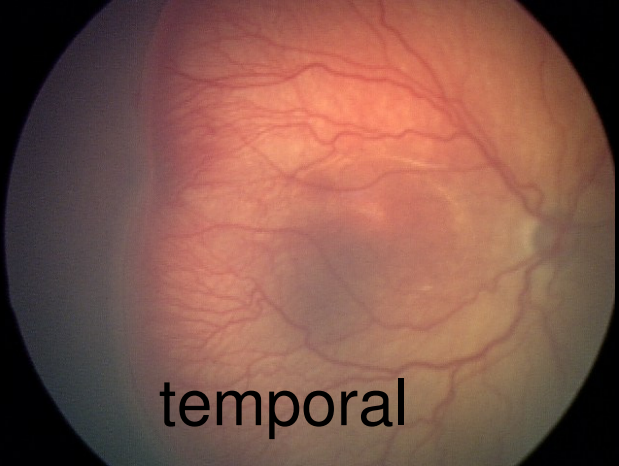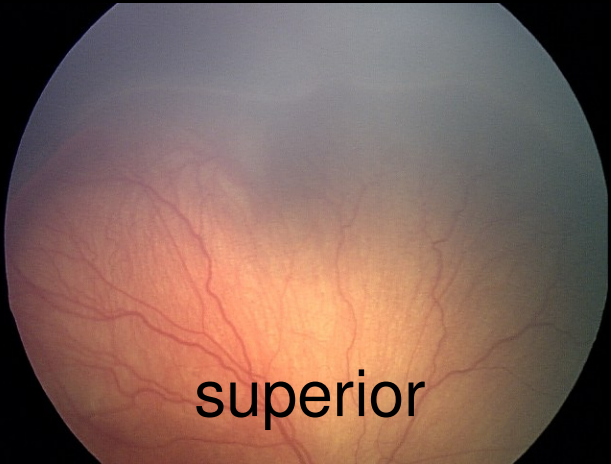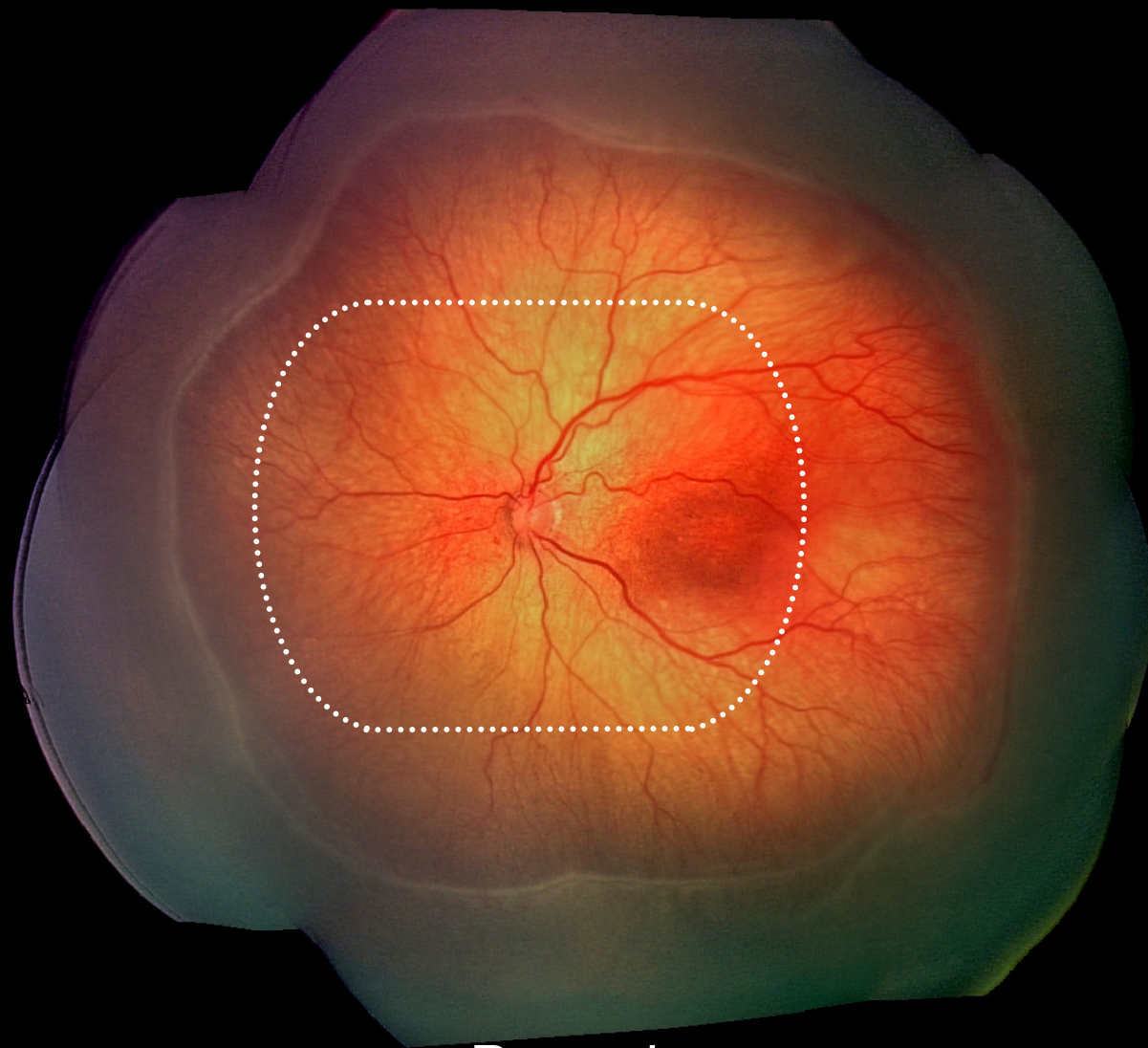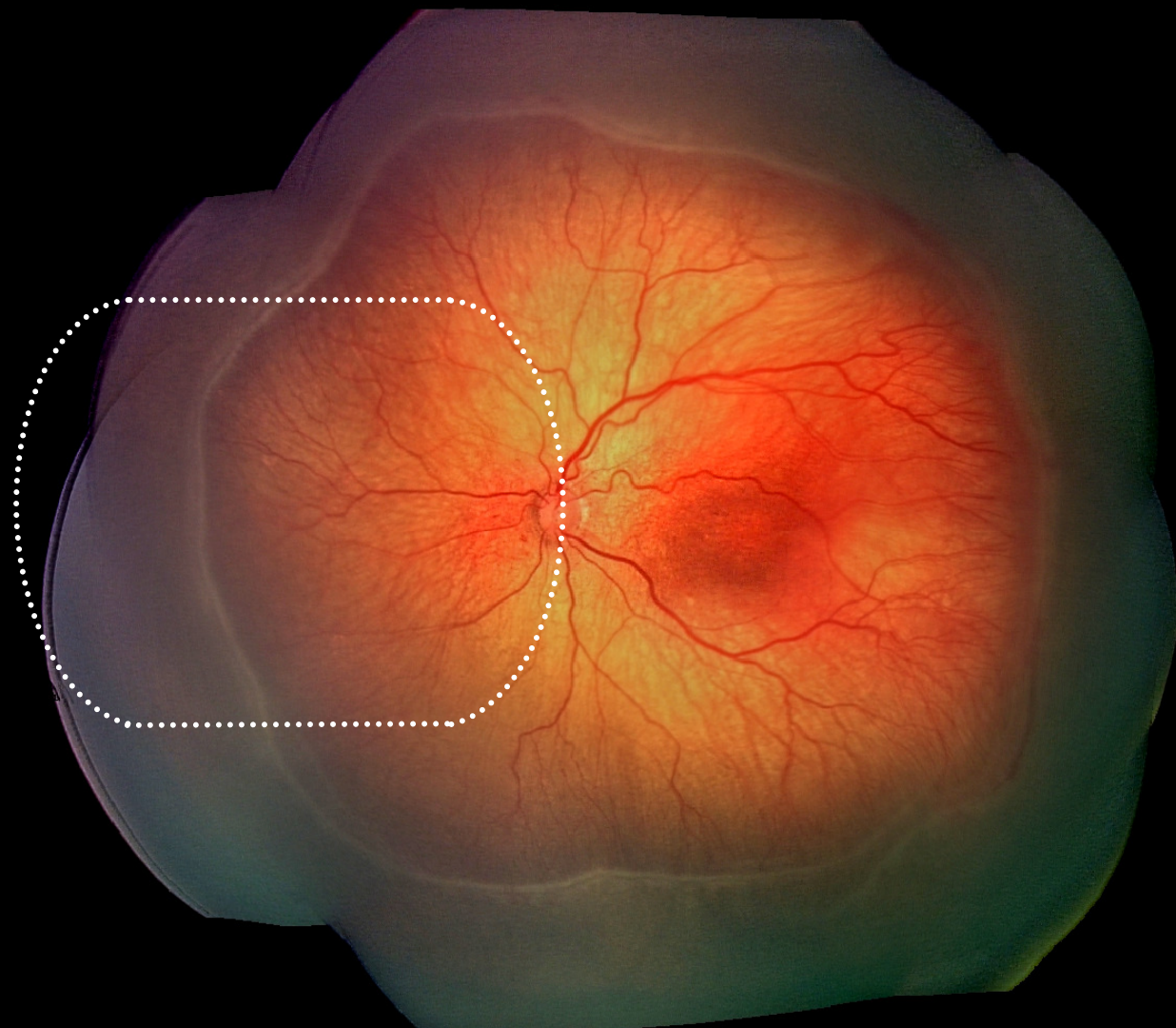
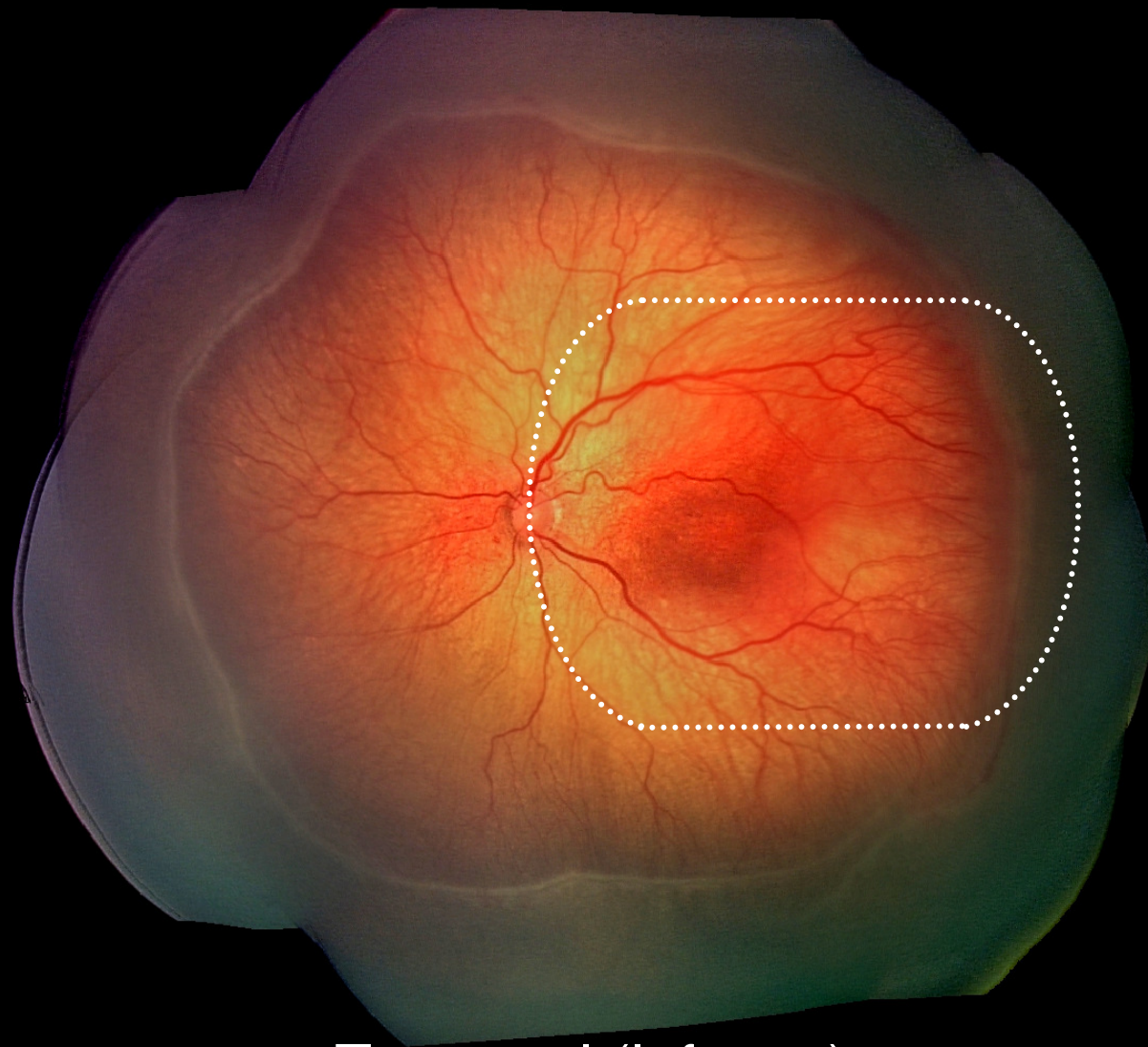


Posterior
(optic nerve in center)

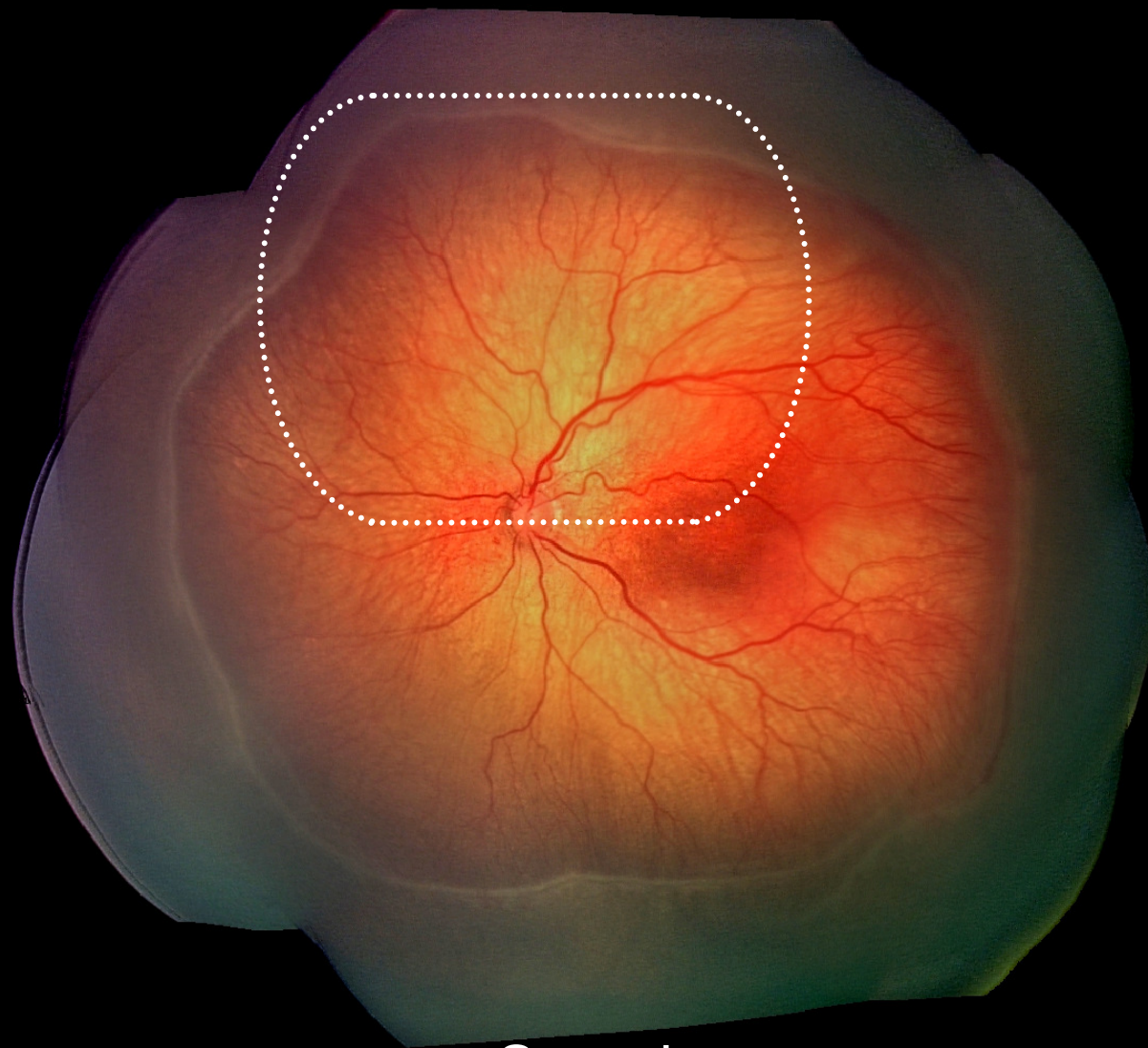


Nasal (left eye)

(optic nerve to the right of the frame)

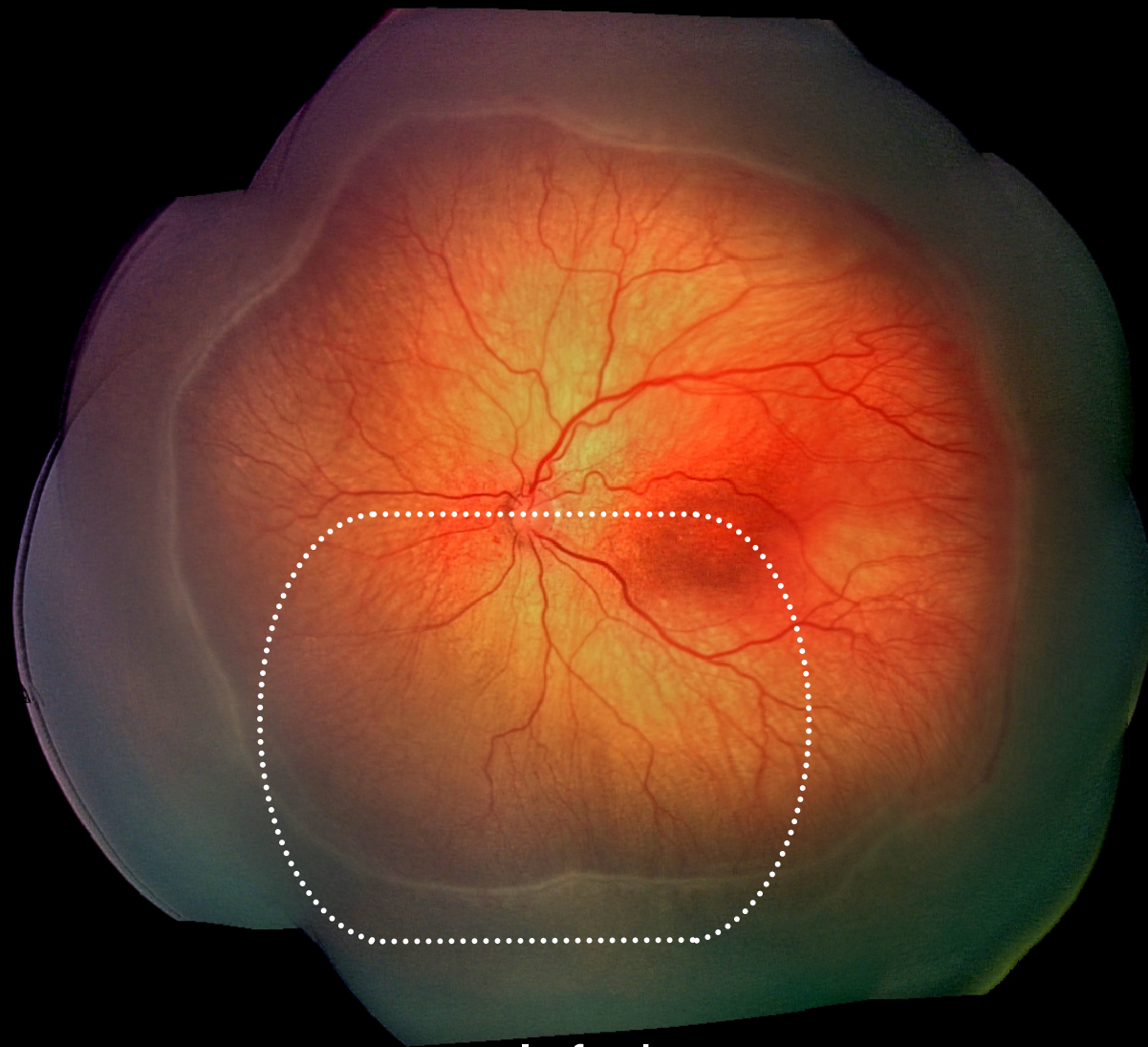


Temporal (left eye)
(optic nerve to the left of the frame)



Superior

(optic nerve at the bottom of the frame)



Inferior

(optic nerve at the top of the frame)